



BRIEF REPORT

Open Access

Covid-19, Ecmo and Coagulation: A Bizarre Triangle with A Happy EndS. Veiras^{1*}, M.Eiras, A. Martínez¹, S. Selas¹, M. Taboada¹ and J. Alvarez²¹Anaesthesiology and Postoperative Intensive Care Department, University Hospital of Santiago de Compostela.²Head of Department and Dean of the Medicine Faculty, University of Santiago de Compostela.

ARTICLE HISTORY

Received Aug 08, 2020

Accepted Aug 17, 2020

Published Aug 20, 2020

KEYWORDS

Covid-19, Coagulopathy, ECMO,
Remdesivir**Clinical Case Resume**

A 44-year-old man (arterial hypertension and overweight) was admitted to our Postoperative Intensive Care Unit on April 6th. On March 15th, he had started anosmia and odynophagia at home and received antimicrobial therapy, improving symptoms. On March 30th he started feeling general discomfort, myalgia and diarrhoea with fever up to 39 degrees Celsius.

On April 5th he came to Emergency Department in our hospital. Covid PCR was positive in nasopharyngeal swab. Furthermore, blood sample analysis revealed acute renal failure with creatinine 8,5 mg/dL and urine sediment suggestive for urinary tract infection.

He was transferred to our Unit with the aim of being monitored due to both infective-Covid and Urine- findings. Inflammatory markers were elevated (LDH 549.0 U/L; Ferritine 3286.0 ng/mL; IL-6 53.3 pg/mL; DD 3466.0 ng/mL and PCR 17.23 mg/dL). No significant radiological findings were observed in admission (see RADIOLOGICAL EVOLUTION in image 1).

The patient was slightly dyspnoeic but SpO₂ was 99% under oxygen flow cannula 6 litres per minute. Instructions for self-prone positioning as long as possible and physiotherapy assistance were made. Fluids and diuretics were started to treat renal insufficiency (prerenal aetiology most probable).

On April 7th, acute respiratory failure with deep hypoxia obliged to orotracheal intubation, deep sedation, neuromuscular blocking

and prone positioning for 16 hours.

Next morning prone was reversed to supine position resulting again in deep hypoxia despite inspired oxygen fraction of 100%.

Chest X Ray, Pulmonary and cardiac echo study were performed. Non-cardiac abnormalities could be observed. Pulmonary echo showed coalescence of B lines in both pulmonary apex and dynamic bronchogram in both basal pulmonary lobes. The medical team agreed veno-venous ECMO implant and it was performed through jugular and femoral veins cannulation.

Remdesivir was initiated in this patient after discussing about his suitability to receive this restricted drug. Informed consent was obtained from patient's sister in order to administer remdesivir as a compassionate use.

Remdesivir therapy was completed for ten days.

As described in the table below, inflammatory markers (Reactive Protein C, Ferritin, IL-6) significantly reduced their plasmatic values after remdesivir started. Systemic oxygenation slowly improved by ECMO therapy for nineteen days.

Systemic anticoagulation was initiated when ECMO was implanted with APTT ranges about 50 seconds.

Surprisingly, D Dimer values did not improve, on the contrary, they increased daily and reached a number > 80000 ng/mL. Vascular echo studies were daily performed to discard thrombosis.

Contact S. Veiras ✉ veiras1@gmail.com 📧 Anaesthesiology and Postoperative Intensive Care Department, University Hospital of Santiago de Compostela.

© 2020 The Authors. This is an open access article under the terms of the Creative Commons Attribution NonCommercial ShareAlike 4.0 (<https://creativecommons.org/licenses/by-nc-sa/4.0/>).

Table 1: Inflammatory markers and coagulation values during admission

	5/4	6/4	7/4	10/4	14/4	17/4	21/4	22/4	23/4	24/4	25/4	26/4	27/4	29/4
D-D	3466	2017	849	1829	10214	17289	62008	73232	-----	84118	84465	65070	28856	15713
Protein C	17,23	10,35	9,09	5,85	1,828	0,397	0,122	----	----	----	2,69	1,02	0,58	0,9
Ferritin	3286	2774	2738	2057	1185	686	930	511	333	259	325
IL6	53,3	92	13,5	54,8	11,6	3,6	3	2	2	<2	4,7
LDH	549	868	778	500	1300	955	862	398	346	267	285
Plat	141	106	112	134	157	124	103	84	51	97	88	80	202
PT	11,4	11,1	---	10,7	12,7	12,3	11,8	12,1	11,5	12	11,7
Fibrinogen	-----	357	----	333	377	284	220	218	----	----	172	97	---	464
ProBNP	183	---	800	151	119	70	-----	-----	-----	-----	-----	-----	-----	-----

D-D (D-Dimer) measured in ng/mL Protein C mg/dL

Ferritin ng/mL IL6 pg/mL LDH U/L

Platelets ($\times 10^3/\mu\text{L}$) Fibrinogen (mg/dL)

ProBNP (Pro-Brain Natriuretic Peptide) pg/dL

After fifteen days on ECMO, thrombocytopenia was observed, though no significant increase in platelet antiPF4 antibodies was observed to think about heparin induced thrombocytopenia (HIT). Complement factors were also measured being into normal values and haemolysis indicators discarded haemolytic procedure.

Nevertheless, the patient started to bleed from nasal, oral and rectal mucoses, platelet transfusion was programmed each eight to twelve hours trying to achieve a platelet count over 100000 and packed red cells were also transfused with the goal of maintaining haemoglobin over 10 g/dL.

Haematologists suggested argatroban anticoagulation to avoid heparin even when HIT was not clarified.

Argatroban [1] does not have any antidote in case of bleeding and it is recommended to maintain platelets over 80000 during this therapy. It was hard for us to increase patient's platelet counts even with transfusion, so we decided to speed up ECMO weaning and programmed ECMO explant in a 72 hours period.

Meanwhile, high dose of steroids were administered and heparin administration was stopped.

ECMO was successfully explanted on day 19th. D Dimer values dramatically decreased since then and still do.

Patient was successfully extubated and transfer to hospitalization unit was made on May 5th.

Coagulation Disorders Associated to Covid-19

This new pandemic disease of Covid-19 is forcing us as physicians to rapidly understand bizarre scenarios we did not face before. Quite much is known about sepsis-induced coagulopathy [2] (SIC) and its severity score including three items: PT, Platelets account and SOFA score including respiratory, cardiovascular, renal and hepatic parameters.

We are also aware of disseminated intravascular coagulation concept (DIC) [3] and its scoring system including platelet count,

D-Dimer levels, fibrinogen levels and PT.

But Covid-19 associated coagulopathy is something else than SIC or DIC. It seems to be something in between coagulation and immunologic response. This is a not new concept, immunothrombosis [4] where an imbalance between coagulation and inflammation exists, leading to extreme inflammatory response and diffuse fibrin deposits in vascular capillary bed and alveoli.

Activated platelets, neutrophils, endothelial cells, neutrophil extracellular traps, micro particles, and coagulation proteases, participate in the complex process of immunothrombosis, which is a key event in ARDS pathophysiology and could perfectly explain Covid-19 clinical findings.

Particularities of Our Case

In our patient, predominant finding was D-Dimer levels extraordinary elevated (>80.000 ng/mL). Even under systemic heparin for ECMO anticoagulation, DD

levels were monstrous and made us think about a poor survival in this patient [5,6,7,8] or maybe a poor gas exchange in membrane oxygenator [9]. No gas exchange problems were observed. DD levels dramatically decreased after ECMO explant. Before transferring the patient to the hospitalization floor, a thoracoabdominal tomographic study (with ev contrast administration) did not show any thrombus in large venous trunks. Which was the cause for such a high DD? Was it only due to Covid infection? But the only parameter that remained high was DD after remdesivir therapy while other inflammatory and infectious markers improved.

Viscoelastic tests were performed twice in this patient after two weeks under ECMO therapy (see figures below). Hypercoagulability has been widely described in Covid patients [10,11] with ROTEM patterns exhibiting wide A5 values and short clot firmness times (CFT), but in a late phase of the disease, tendency to hypo coagulation has been described [12-14]. Our patient showed this hypocoagulability tendency when thrombocytopenia emerged (see figures 1 and 2).

This patient was the only one in our unit receiving remdesivir therapy. Inflammatory markers and procalcitonin rapidly decreased though Covid PCR was still positive when patient was discharged from Critical Care.

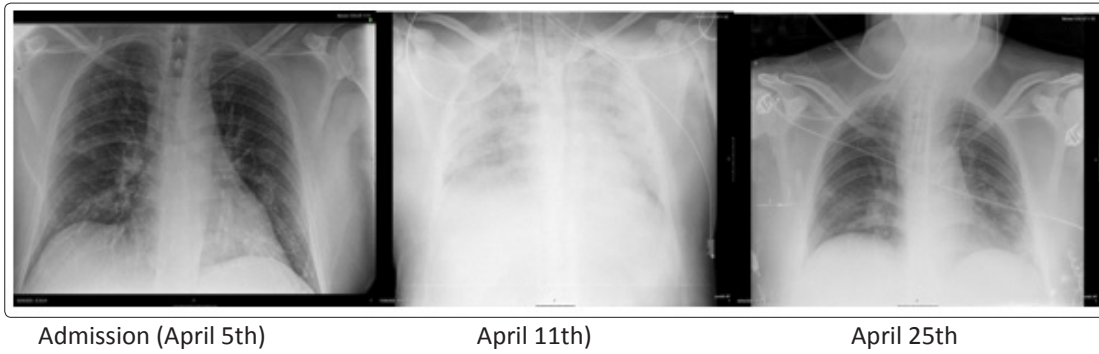


Image 1: Radiological evolution

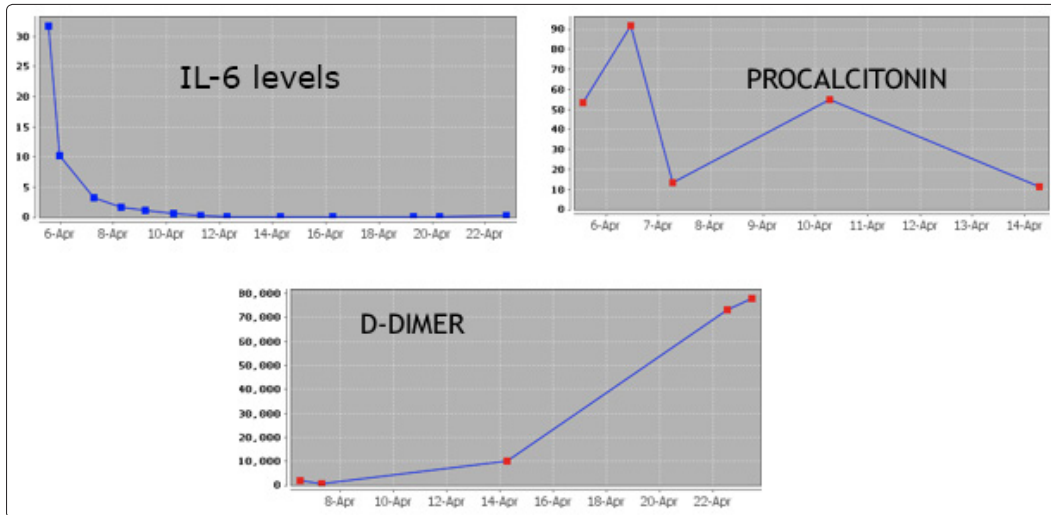
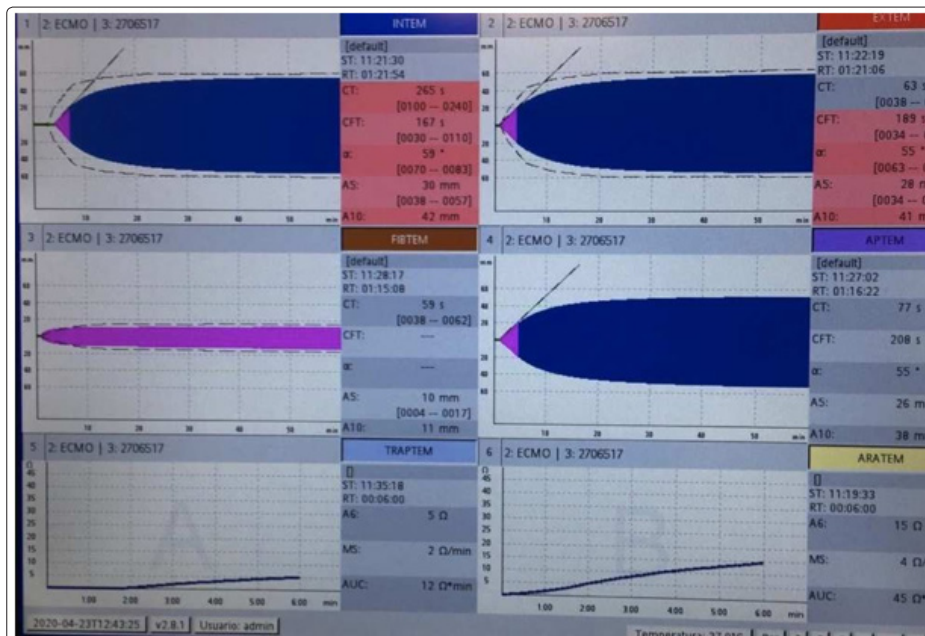
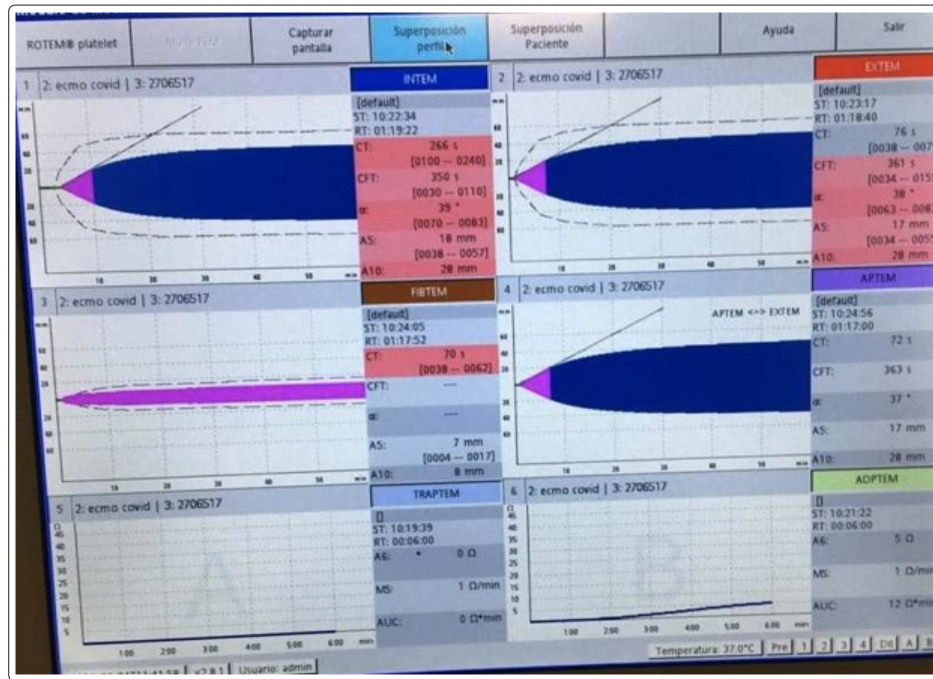


Figure 1: Graphic evolution of IL-6, Procalcitonin and D-Dimer



ROTEM 1: April 23rd. Patient is under heparin treatment to anticoagulate ECMO circuit. Platelet mapping (thrombin activator and araquidonic acid receptors) reveals platelet dysfunction.



ROTEM 2: April 24th. Thrombocytopenia has emerged, HIT is not clarified due to no significant elevation in platelet anti PF4 antibodies. Platelet mapping is still evidencing dysfunction.

Figure 2: Thromboelastogram studies

References

[1] Sun Z, et al. Comparisons of argatrobam to lepirudin and bivalirudin in the treatment of heparin-induced thrombocytopenia: a systematic review and meta-analysis. *Int J Hematol* 2017; 106(4): 476-483.

[2] Iba T, New criteria for sepsis-induced coagulopathy (SIC) following the revised sepsis definition: a retrospective analysis of a nationwide survey et al. *BMJ Open* 2017; 7:e017046. doi:10.1136/bmjopen-2017-017046..

[3] Levy M, Sivapalaratman S. Disseminated intravascular coagulation: an update on pathogenesis and diagnosis. *Journal Expert review of Hematology*. 2018; Vol 11: 8

[4] Frantzeskaki F et al, Immunothrombosis in Acute Respiratory Distress Syndrome: Cross Talks between Inflammation and Coagulation. *Respiration* 2017; 93:212–225 DOI: 10.1159/000453002

[5] Tang N, Li D, Wang X, Sun Z. Abnormal coagulation parameters are associated with poor prognosis in patients with novel coronavirus pneumonia. *J Thromb Haemost* 2020. Doi: 10.1111/jth.14768. [Epub ahead of print]

[6] Wu C, Chen X, Cai Y, Xia J, Zhou X, Xu S, Huang H, Zhang L, Zhou X, Du C, Zhang Y, Song J, Wang S, Chao Y, Yang Z, Xu J, Zhou X, Chen D, Xiong W, Xu L, et al. Risk Factors Associated With Acute Respiratory Distress Syndrome and Death in Patients With Coronavirus Disease 2019 Pneumonia in Wuhan, China. *JAMA Intern Med* 2020: Doi: 10.1001/jamainternmed.2020.0994. [Epub ahead of print]

[7] Gao Y, Li T, Han M, Li X, Wu D, Xu Y, Zhu Y, Liu Y, Wang X, Wang L. Diagnostic Utility of Clinical Laboratory Data Determinations for Patients with the Severe COVID-19. *J Med Virol* 2020: Doi: 10.1002/jmv.25770. [Epub ahead of print]

[8] Zhou F, Yu T, Du R, Fan G, Liu Y, Liu Z, Xiang J, Wang Y, Song B, Gu X, Guan L, Wei Y, Li H, Wu X, Xu J, Tu S, Zhang Y, Chen H, Cao B. Clinical course and risk factors for mortality of adult inpatients with COVID-19 in Wuhan, China: a retrospective cohort study. *Lancet* 2020; 11: Pii: S0140-6736(20)30566-3. Doi: 10.1016/S0140-6736 (20)30566-3. [Epub ahead of print]

[9] Basken R et al, Predictors of Oxygenator Exchange in Patients Receiving Extracorporeal Membrane Oxygenation. *J Extra Corpor Technol*. 2019: 51:61–6

[10] Spiezia L et al, COVID-19-Related Severe Hypercoagulability in Patients Admitted to Intensive Care Unit for Acute Respiratory Failure. *Thromb Haemost* April 2020. DOI https://doi.org/ 10.1055/s-0040-1710018. ISSN 0340- 6245.

[11] Panigada M et al, Hypercoagulability of COVID-19 patients in Intensive Care Unit. Report of Thromboelastography Findings and other Parameters of Hemostasis. *J Thromb Haemost* 2020; doi:10.1111/JTH.14850

[12] Görlinger K et al, COVID-19 associated Coagulopathy: What do we know already and what are the knowledge gaps?

[13] J. Grein, N. Ohmagari, D. Shin et al, Compassionate Use of Remdesivir for Patients with Severe Covid-19. *NEJM.org N Engl J Med*, 2020: DOI: 10.1056/NEJMoa2007016

[14] Giannisa D et al, Coagulation disorders in coronavirus infected patients: COVID-19, SARSCoV-1, MERS-CoV and lessons from the past. *J Clin Virol*. 2020: 127:104362. doi: 10.1016/j.jcv.2020.104362.